

MOOMIN, A., MENSAH, K.B., FORKUO, A., ADU-GYAMFI, P.K.T. and ANSAH, C. 2020. Ethanolic stem bark extract of terminalia ivorensis A. Chev. protects against potassium dichromate-induced nephrotoxicity in rats. *Scientific African* [online], 8, article number e00410. Available from: <https://doi.org/10.1016/j.sciaf.2020.e00410>

Ethanolic stem bark extract of terminalia ivorensis A. Chev. protects against potassium dichromate-induced nephrotoxicity in rats.

MOOMIN, A., MENSAH, K.B., FORKUO, A., ADU-GYAMFI, P.K.T. and ANSAH, C.

2020

© 2020 Published by Elsevier B.V. on behalf of African Institute of Mathematical Sciences.

OpenAIR
@RGU

This document was downloaded from
<https://openair.rgu.ac.uk>





Ethanollic stem bark extract of *Terminalia ivorensis* A. Chev. protects against potassium dichromate–induced nephrotoxicity in rats



Aliu Moomin^{a,c}, Kwesi Boadu Mensah^{a,*}, Arnold Donkor Forkuo^a, Paa Kofi Tawiah Adu-Gyamfi^b, Charles Ansah^a

^a Dept of Pharmacology, Faculty of Pharmacy and Pharmaceutical Sciences, College of Health Science, Kwame Nkrumah University of Science and Technology, Kumasi, Ghana

^b Department of Nursing and Midwifery, Faculty of Health and Allied Sciences, Pentecost University College Accra, Accra, Ghana

^c School of Pharmacy and Life Sciences, Robert Gordon University, Aberdeen, UK

ARTICLE INFO

Article history:

Received 3 December 2019

Revised 20 February 2020

Accepted 22 April 2020

Keywords:

Nephroprotection

Oxidative stress

Glutathione

Superoxide dismutase

Traditional medicine

ABSTRACT

Objective: The plant *Terminalia ivorensis* is used in traditional medicine as a diuretic and in the management of renal failure. We reported previously that the ethanol stem bark extract of the plant protects against gentamicin-induced renal and hepatic damage in rats. To further elucidate the mechanism of its renoprotective activity, we studied the effects of the extract on Potassium dichromate–induced nephrotoxicity in rats. The present study assessed the effectiveness of the ethanol stem bark extract of *Terminalia ivorensis* - against renal oxidative injury evoked by potassium dichromate.

Methods: Adult Sprague Dawley rats pre-treated with (100–1000 mg/kg *p.o.* bwt) of *Terminalia ivorensis* extract for 5 days were challenged with a single dose of Potassium dichromate (20 mg/kg *Sc*) in the neck region on the 4th day. On the sixth day, renal function and markers of oxidative injury were assessed.

Results: *Terminalia ivorensis* (300–1000 mg/kg *p.o.*) pre-treatment dose dependently prevented decreases in urine output in rats challenged with a nephrotoxic dose of Potassium Dichromate. The extract also protected the rats against Potassium dichromate-induced rise in serum electrolytes, urea and creatinine. Furthermore, it dose dependently prevented Potassium dichromate-induced decrease in renal glutathione (GSH) levels whereas tissue oxidative enzymes Superoxide dismutase (SOD) and catalase were protected from damage. Markers of lipid peroxidation such as level of renal Malondialdehyde (MDA) and myeloperoxidase (MPO) also decreased dose dependently when compare with Potassium dichromate treated groups. The extract also protected the histomorphology of the kidney against Potassium dichromate induced damage.

Conclusion: The ethanol stem bark extract of *Terminalia ivorensis* protects kidney against Potassium dichromate-induced renal damage.

© 2020 Published by Elsevier B.V. on behalf of African Institute of Mathematical Sciences / Next Einstein Initiative.

This is an open access article under the CC BY-NC-ND license. (<http://creativecommons.org/licenses/by-nc-nd/4.0/>)

* Corresponding author

E-mail addresses: a.moomin@rgu.ac.uk (A. Moomin), kbmensah.pharm@knust.edu.gh (K.B. Mensah), afdonkor.chs@knust.edu.gh (A.D. Forkuo).

Introduction

Renal failure due to kidney damage and associated renal insufficiency is an important adverse effect of common therapeutic agents such as non-steroidal anti-inflammatory drugs (NSAIDs) and antibiotics such as aminoglycosides, vancomycin and polyenes [1–3] which limits their clinical usefulness. Furthermore, kidney diseases appear to increase globally [4] and more people now require either transplant or frequent dialysis to improve their quality of life. Drug-induced nephropathy and renal failure secondary to pre-existing medical conditions place enormous economic burden on the individual and national health care systems. In Ghana the cost of dialysis per year is above \$9000 and the cost of a kidney transplant is about \$6000 [5]. The search for new nephroprotective agents that enhance renal tissue regeneration will reduce the cost of managing renal diseases and give clinicians greater leverage in their choice of medicines for the management of renal diseases.

The tropical plant, *Terminalia ivorensis* is reported to be useful in the treatment of ulcers, cuts, sores, wounds, general body pains, hemorrhoids, diuresis, malaria and yellow fever [6–10] Because of its purported anti-inflammatory activity in traditional medicine [11], we had reasoned that its effects on the kidney may be similar to that of NSAIDs. However, recent work in our laboratory showed that the ethanol extract of the plant protected rats against gentamycin-induced renal damage [12]. Furthermore, the plant extract stimulated renal tissue regeneration following damage induced by gentamycin. As to whether the extract has the potential to protect against other nephrotoxicants is currently unknown. The objective of the present study was to assess the potential of the ethanol extract of the stem bark of *Terminalia ivorensis* to reverse renal damage caused by Potassium dichromate, a nephrotoxic hexavalent chromium that induces oxidative stress and cytotoxicity in renal cells [13–15]

Materials and methods

Preparation of plant material

The stem bark of *Terminalia ivorensis* was collected from Asakraka Kwahu in the Eastern region of Ghana in September 2014. The samples were authenticated at the Department of Herbal Medicine, Kwame Nkrumah University of Science and Technology, Kumasi, Ghana, and a specimen with voucher number FP/095/10 deposited at the Department's herbarium. The harvested stem bark was washed, air dried and powdered using a hammer mill. Ethanol (70%) was used to extract the sample by adding 5.0 L to every 1 kg of the powdered sample and the mixture allowed to stand for 72 h. The supernatant was filtered and evaporated using a Rota evaporator at a temperature of 60 °C in vacuo. The wet mass was then oven dried at 55 °C and the yield obtained was 24.3% w/w. The sample was kept in refrigerator and routinely reconstituted in distilled water for oral administration when needed to rats.

Chemicals

Ethanol, glacial acetic acid, n-butanol, hydrogen peroxide and Tris – HCl, were obtained from BDH chemicals Ltd, Poole, England. Phenazine methosulphate 5,5' – dithiobis-(2-nitrobenzoic acid), o-dianisidine, nitroblue tetrazolium (NBT) reduced nicotinamide adenine dinucleotide (NADH), thiobarbituric acid (TBA), trichloroacetic acid (TCA) and Potassium dichromate were obtained from Sigma – Aldrich chemicals Co., St Louis, Missouri, USA.

Phytochemical screening

Qualitative phytochemical screening for bioactive molecules of the crude stem bark extract was carried-out based on methods described elsewhere by Sofowora [16].

HPLC fingerprinting

Varying concentrations of extracts (0.1 – 10 mg/ml) were prepared for HPLC analysis. A modular Shimadzu LC-20 system consisting of a LC-20AD pump, a CTO-20AC column oven, an SPD-M20A UV-DAD detector, a CBM-20A interface and a LC-20AT Workstation was utilized. An LC-18 column (250 mm x 4.6 mm i.d. x 5 mm) from Supelco (Bellefonte, USA) was employed, at 30 °C. Separations were done in the isocratic mode, using acetonitrile:water (40:60; v/v) at a flow rate of 1 mL min⁻¹; with an injection volume of 20 µL; UV detection was at 350 nm.

Experimental animals

Sprague – Dawley rats (200 – 240 g) of both sexes obtained from the Animal house of the Department of Pharmacology, KNUST were acclimatized on a 12-hour light and dark cycle for one week before the experiments. They were kept in standard aluminum laboratory cages (34 × 47 × 18 cm) with fine wood shavings as bedding and had free access to feed and water *ad libitum*. All experimental procedures were in accordance with the Declaration of Helsinki and the Guiding Principles in the Care and Use of Animals and were subsequently approved by departmental ethics committee (PCOL/ETH/122015).

Acute toxicity study of ethanol extract of Terminalia ivorensis in rats

The method used for the acute study was as described elsewhere [17]. Thirty Sprague – Dawley rats (200 – 240g) of both sexes were grouped into six ($n = 5$). Group I (control) received vehicle (distilled water) only. Groups II – VI received 100, 500, 1000, 3000 and 5000 mg/kg of extract orally by gavage respectively. The animals were observed every 30 min over a 24-hour period for general behavioral, physiological changes including CNS stimulation and depression, autonomic changes and lethality. The animals were further observed for 14 days for possible latent toxicity of the extract.

Effect of Terminalia ivorensis extract on Potassium dichromate – induced nephrotoxicity

The method used was as described previously by Aslam *et al.* [18]. Thirty (30) Sprague – Dawley rats (180 – 240 g) of both sexes were weighed and placed into five groups ($n = 6$). They were left to acclimatize for one week with fresh water and feed *ad libitum*.

The groups were subsequently treated initially as follows:

- Group I (control): received distilled water (1 mL/kg/day orally) for 5 days.
- Group II: received distilled water (1 mL/kg/day orally) for 5 days.
- Group III: received extract (100 mg/kg/day orally) for 5 days.
- Group IV: received extract (300 mg/kg/day orally) for 5 days.
- Group V: received extract (1000 mg/kg/day orally) for 5 days.

All the groups except group I received a single dose of Potassium dichromate (1 ml, 20 mg/kg *s.c*) on day 4 in the cervical region. On the 5th day, all animals were placed in metabolic cages for 24 – hour urine collection. This was followed by weighing and collection of blood samples from the retro – orbital venous plexus of all animals on the sixth day for the estimation of serum electrolytes and biochemistry. All animals were then sacrificed by cervical dislocation and their kidneys were removed, washed with normal saline, weighed and the right kidney preserved for histopathological studies. The left kidney was used for the preparation of post-mitochondrial supernatant.

Estimation of serum biochemical parameters

For the estimation of urea, creatinine and electrolytes collected blood samples were centrifuged at 5000 r.p.m for 10 min. Biotecnica BT 3000 Targa chemistry analyzer and Flexor Junior Auto analyzer were used for the assessment of renal biochemistry and electrolytes respectively [18].

Preparation of tissue homogenate and estimation of biomarkers of oxidative stress

Left kidneys were cleaned free of extraneous material and immediately perfused with ice – cold saline (0.85% sodium chloride), homogenized in chilled phosphate buffer (0.1 M, pH 7.4) containing KCl (1.17%) with Potter-Elvehjem homogenizer (Ultra-Turrax T25, Janke & Kunkel IKA- Labortechnik, Staufen, Germany). The homogenate was filtered through a clean material and centrifuged with Hettich-zentrifugen (Micro 220R, Germany) at 800 X g for 5 min at 4 °C to separate the debris. The supernatant obtained was again centrifuged at 5000 rpm for 30 min at 4 °C to obtain the post – mitochondrial supernatant (PMS), which was used as the enzyme source for the biochemical estimations. All the assays were completed within 24 h of animal sacrifice (Khan & Sultana 2005). Methods described elsewhere were used to assay reduced glutathione, superoxide dismutase, catalase, lipid peroxidation and myeloperoxidase activity respectively [19–23].

Histopathological analysis

Right kidneys of rats were fixed in 10 % neutral buffered formalin solution for histopathological processing. Sections of the kidneys were stained with hemotoxylin and eosin, and observed under a Leica DM 750 microscope (ICC50 HD, JosHansen, Germany) using a X400 magnification.

Statistical analysis

GraphPad Prism 6.0 was used and differences between groups were analyzed using One – Way Analysis of Variance (ANOVA) followed by Sidak's multiple comparison test. All results were presented as mean \pm SEM.

Results

Phytochemistry and HPLC analysis

Phytochemical analysis indicated the presences of flavonoids, terpenoids, alkaloids, condensed tannins, Saponins, cardiac glycosides, anthraquinones and steroids. HPLC analysis showed 3 major compounds at different retention (Figure S1).

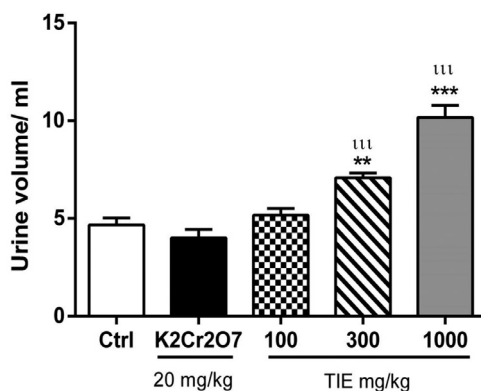


Fig. 1. Effects of Potassium dichromate (20 mg/kg) and *Terminalia ivorensis* extract (TIE) (100, 300, 1000 mg/kg) on 24 – hour urine output. ** $p < 0.01$, *** $p < 0.001$ as compared to the control group (one-way ANOVA followed by Sidak's post hoc test) and ††† $p < 0.001$ as compared to K₂Cr₂O₇ group (one-way ANOVA followed by Sidak's post hoc test).

Table 1

Effects of extract of *Terminalia ivorensis* and Potassium dichromate on serum biochemistry and electrolytes in rats.

Treatment	Creatinine ($\mu\text{mol/L}$)	Urea (mmol/L)	Sodium (m/L)	Potassium (m/L)	Chloride (m/L)
Control: distilled 10 ml/kg	27.83 \pm 1.85	5.09 \pm 0.11	121.70 \pm 3.25	12.85 \pm 0.48	84.50 \pm 2.35
K ₂ Cr ₂ O ₇ 20 mg/kg	358.70 \pm 34.56***	56.55 \pm 3.63***	136.30 \pm 2.81**	15.70 \pm 0.55**	95.67 \pm 3.80*
TIE 100 mg/kg + K ₂ Cr ₂ O ₇	255.50 \pm 28.47***†	53.33 \pm 7.02***	129.70 \pm 2.29	14.15 \pm 0.47	89.33 \pm 1.45
TIE 300 mg/kg + K ₂ Cr ₂ O ₇	160.50 \pm 6.84***††	37.81 \pm 2.57***†	128.00 \pm 1.73	12.92 \pm 0.33†	89.50 \pm 2.01
TIE 1000 mg/kg + K ₂ Cr ₂ O ₇	123.70 \pm 4.79***†††	27.81 \pm 2.24***†††	124.00 \pm 0.86†	13.03 \pm 0.50†	89.67 \pm 1.20

All data are expressed as mean \pm S.E.M. ($n = 6$), * $p < 0.05$, ** $p < 0.01$ and *** $p < 0.001$ when compared to control group (one-way ANOVA followed by Sidak's post hoc test). † $p < 0.05$ and †† $p < 0.001$ when compared to potassium dichromate group (one-way ANOVA followed by Sidak's post hoc test).

Acute toxicity of ethanol extract of *Terminalia ivorensis* in rats

Administration of the *Terminalia ivorensis* extract (100 – 5000) mg/kg to Sprague – Dawley rats did not cause adverse effects on the general behavior of rats (Table S2). No death was recorded after 14 days of continuous observation. The LD₅₀ was accordingly estimated to be above 5000 mg/kg body weight in rats.

Effects of Potassium dichromate on urine output, serum biochemistry and electrolytes of rats pre-treated with *Terminalia ivorensis* extract

Analyses of 24 – hour urine output showed that *Terminalia ivorensis* pre-treatment dose dependently prevented decrease in urine output in rats challenged with a nephrotoxic dose of Potassium dichromate. This protective effect of the extract was statistically significant at 300 mg ($p < 0.01$) and 1000 mg/kg bwt ($p < 0.001$) (Fig. 1). The extract also protected the rats against Potassium dichromate-induced rise in serum electrolytes, urea and creatinine. Statistically, there were no significant differences in serum electrolytes between rats treated with extract plus Potassium dichromate and untreated controls (Table 1). However, unlike serum electrolytes, serum creatinine and urea of *Terminalia ivorensis* pre-treated animals was significantly higher than that of the untreated controls.

Effect *Terminalia ivorensis* extract pre-treatment on oxidative markers in Sprague-Dawley rats treated with Potassium dichromate

Reduced Glutathione (GSH):- Treatment of rats with Potassium dichromate decreased tissue reduced glutathione (GSH) levels. However, pre-treatment of rats with *Terminalia ivorensis* dose dependently prevented Potassium dichromate-induced decrease in tissue reduced glutathione (GSH) levels (Fig. 2). This effects was statistically significant at 300 and 1000 mg/kg. At these doses of *Terminalia ivorensis*, there was no statistical significant difference between rats pre-treated with the extract and toxicant and untreated controls. The lowest dose of *Terminalia ivorensis* (100 mg/kg) was not effective at protecting tissue reduced glutathione levels against Potassium dichromate.

Superoxide dismutase:- Treatment of rats with Potassium dichromate decreased tissue Superoxide dismutase levels. However, pre-treatment of rats with *Terminalia ivorensis* protected enzymes levels against Potassium dichromate-induced damage (Fig. 3). Unlike its effects on reduced glutathione, all doses of *Terminalia ivorensis* extract significantly protected SOD levels. There was no statistically significant difference in SOD levels between extract plus toxicant treated rats and the untreated controls.

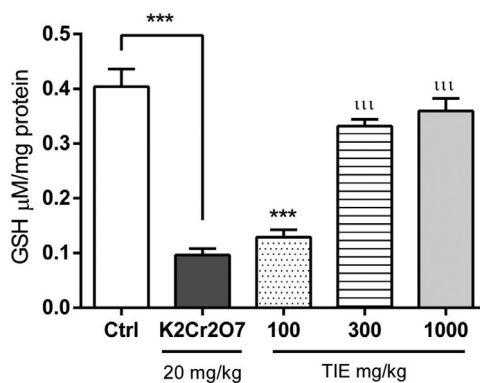


Fig. 2. Effects of Potassium dichromate (20 mg/kg) and *Terminalia ivorensis* extract (TIE) (100, 300, 1000 mg/kg) on GSH levels. *** $p < 0.001$ when compared to control group (one-way ANOVA followed by Sidak's post hoc test). ^{###} $p < 0.001$ when compared to $\text{K}_2\text{Cr}_2\text{O}_7$ group (one-way ANOVA followed by Sidak's post hoc test).

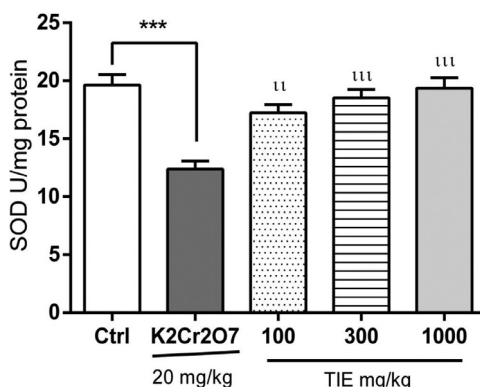


Fig. 3. Effect of Potassium dichromate (20 mg/kg) and *Terminalia ivorensis* extract (TIE) (100, 300, 1000 mg/kg) on SOD levels. *** $p < 0.001$ when compared to control group (one-way ANOVA followed by Sidak's post hoc test). [#] $p < 0.01$ and ^{###} $p < 0.001$ when compared to $\text{K}_2\text{Cr}_2\text{O}_7$ group (one-way ANOVA followed by Sidak's post hoc test).

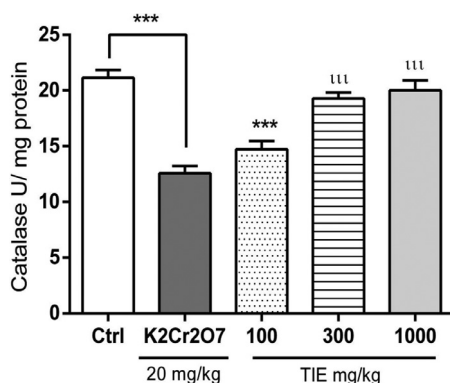


Fig. 4. Effects of Potassium dichromate (20 mg/kg) and *Terminalia ivorensis* extract (TIE) (100, 300, 1000 mg/kg) on catalase levels. *** $p < 0.001$ as compared to the control group (one way ANOVA followed by Sidak's post hoc test), ^{###} $p < 0.001$ when compared to $\text{K}_2\text{Cr}_2\text{O}_7$ group (one way ANOVA followed by Sidak's post hoc test).

Catalase- Similarly, when rats were pre-treated with *Terminalia ivorensis* extract plus Potassium dichromate, the levels of the hem-containing enzyme, catalase, was similar to that of untreated controls. This was statistically significant at 300- and 1000 mg/kg. The protective effects of the extract on catalase was similar to that on SOD. The lowest dose of the extract (100 mg/kg) was not effective in protecting tissue catalase against dichromate-induced damage (Fig. 4).

Malondialdehyde- Treatment of Sprague-Dawley rats with Potassium dichromate resulted in increased lipid peroxidation of polyunsaturated fatty acids. This was characterised by elevated malondialdehyde in the kidneys of treated rats. However,

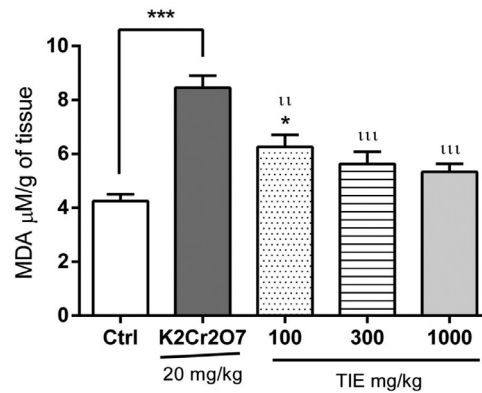


Fig. 5. Effect of Potassium dichromate (20 mg/kg) and *Terminalia ivorensis* extract (TIE) (100, 300, 1000 mg/kg) on MDA levels. * $p < 0.05$ and *** $p < 0.001$ as compared to the control group (one-way ANOVA followed by Sidak's post hoc test), ** $p < 0.01$ and *** $p < 0.001$ when compared to Potassium dichromate group (one-way ANOVA followed by Sidak's post hoc test).

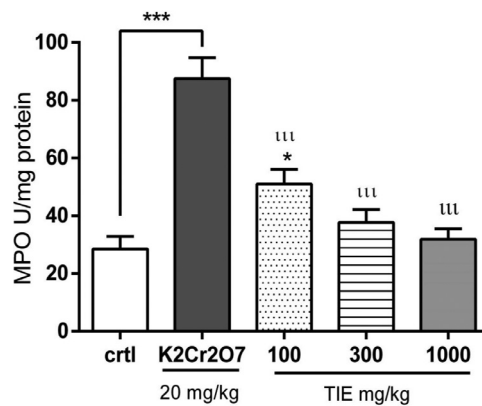


Fig. 6. Effect of Potassium dichromate (20 mg/kg) and *Terminalia ivorensis* extract (100, 300, 1000 mg/kg) on MPO levels. * $p < 0.05$ and *** $p < 0.001$ as compared to the control group (one-way ANOVA followed by Sidak's post hoc test), *** $p < 0.001$ when compared to Potassium dichromate group (one-way ANOVA followed by Sidak's post hoc test).

when rats were pre-treated with *Terminalia ivorensis* (100–1000 mg/kg), the extract protected the kidneys against Potassium dichromate induced lipid peroxidation (Fig. 5). This was characterized by a dose dependent decrease in the tissue levels of malondialdehyde. At 300 mg/kg and 1000 mg/kg, there was no statistically significant difference in the kidney levels of Malondialdehyde in extract plus Potassium dichromate treated groups and untreated control group. Although the low dose of 100 mg/kg of *Terminalia ivorensis* was effective at protecting the kidneys against toxicant assault, the levels of Malondialdehyde was significantly higher than that of untreated control.

Myeloperoxidase- Treatment of Sprague-Dawley rats with Potassium dichromate resulted in increased levels of Myeloperoxidase. Rats pre-treated with the extract expressed decreased levels of Myeloperoxidase when challenge with nephrotoxic dose of Potassium dichromate. The decrease was dose dependent. At the 300 and 1000 mg/kg, there was no significant difference in the treated and untreated controls (Fig. 6)

Histomorphology of kidney sections

Examination of histopathological sections of kidneys indicated that the control group showed normal renal architecture characterized by normal glomerular and tubular histology. Potassium dichromate ($K_2Cr_2O_7$) treated group showed severe vacuolar degeneration, glomerular degeneration, tubular necrosis and tubular cast. However, pretreatment of rats with *Terminalia ivorensis* extract before administration of Potassium dichromate reduced the kidney injury. At 100 mg/kg of extract, there was a moderate kidney damage characterized by vacuolarization, moderate tubular casts, glomerular degeneration and necrosis. Whereas extract at 300 and 1000 mg/kg showed mild vacuolarization, glomerular degeneration, tubular casts and necrosis were observed (Fig. 7).

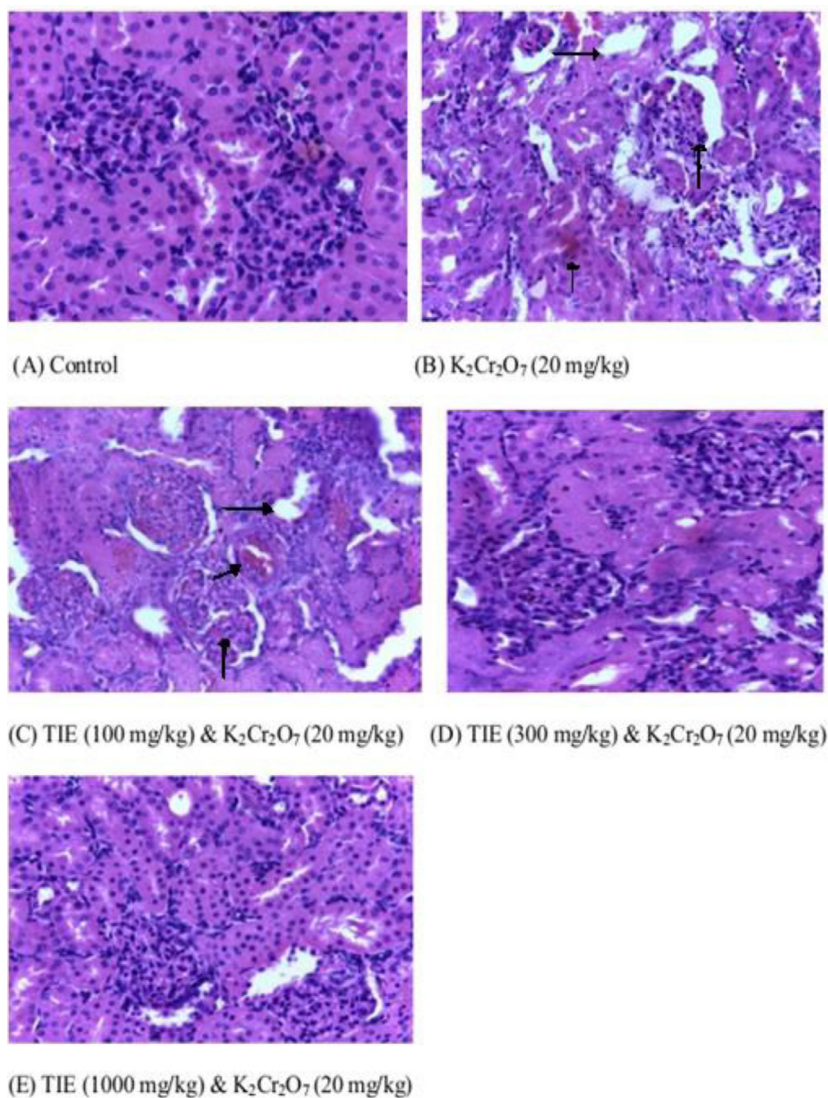


Fig. 7. Effect of Potassium dichromate ($K_2Cr_2O_7$; 20 mg/kg) and *Terminalia ivorensis* extract (TIE100, 300, 1000 mg/kg bwt) on kidney histomorphology. Moderate kidney damage characterized by vacuolarization, moderate tubular casts, glomerular degeneration and necrosis have been indicated with arrows.

Discussion

Medicinal plants play a vital role as first line treatment for various diseases due to their low cost and easy accessibility. Traditionally, herbalists have used *Terminalia ivorensis* for ulcers, wounds, diuretic, general body pains, malaria, hemorrhoids and yellow fever [6,12]. It is also used as timber and antitussive. It has been proven scientifically to possess antihypertensive, anti-hyperglycemic, antiparasitic, anti-inflammatory and anti-arthritic properties [24–26].

Further to our earlier work on the potential nephroprotective activity of ethanol extract of *Terminalia ivorensis* against gentamicin-induced renal damage, the present work examined the potential nephroprotective effect of *Terminalia ivorensis* on renal oxidative stress and consequent damage induced by Potassium dichromate. In the acute toxicity experiment, no death was recorded when the extract was administered to rats. The median lethal dose (LD₅₀) was therefore estimated to be above 5000 mg/kg body weight. As reported previously, any substance with LD₅₀ beyond 1000 mg/kg body weight should be considered safe or of low toxicity when orally administered [27]. TIE on this basis can be classified to be of low toxicity.

In the present study, administration of Potassium dichromate (20 mg/kg) induced renal dysfunction which was evident by significant elevation in serum urea, creatinine, electrolytes and decreased body weight with histological damage in the kidneys. Pre-treatment of rats with *Terminalia ivorensis* ethanol stem bark extract before induction of nephrotoxicity significantly increased the urine output when compared to the Potassium dichromate treated group. The observed increase in

urine output and alteration of serum electrolytes levels and renal markers may partly explain its purported antihypertensive property [28].

Oxidative stress is strongly linked to many degenerative diseases including kidney damage. The ability of a chemical to suppress the generation and activity of free radicals can prevent damage to organs and essential biochemical processes [29]. Superoxide dismutase catalyzes the conversion of superoxide radicals to oxygen and hydrogen peroxide, which is the first line of defense against reactive oxygen species [30,31]. Catalase then decomposes hydrogen peroxide to water and oxygen [32,33]. GSH is a soluble tripeptide that acts as an antioxidant and a redox buffer [33,34].

During nephrotoxicity, there is a build-up of reactive species, which results in an oxidative degradation of lipids and other lipid-containing structures in a process termed lipid peroxidation [35]. Lipid peroxidation was quantified in terms of malondialdehyde (MDA) formed in our study. A high level of MDA indicates high level of cell membrane degradation due to lipid peroxidation [35,36]. Myeloperoxidase (MPO) is also involved in the development of tissue damage and increased levels of free MPO are observed in tissues with inflammation [37]. MPO converts hydrogen peroxide and chloride ions into hypochlorous acid (HOCl) and other highly reactive products [38,39].

In this study, nephrotoxicity induced by Potassium dichromate was evident by diminished SOD, GSH and catalase levels as well as elevated MDA and MPO levels. Extract pre-treated animals showed significantly enhanced superoxide dismutase (SOD), reduced glutathione (GSH) and catalase activities. The formation of myeloperoxidase and the lipid peroxidation product (MDA) were also observed to be significantly reduced in the groups treated with the extract when compared to the Potassium dichromate group. The activity shown by *Terminalia ivorensis* ethanolic stem bark extract might be due to its ability to induce antioxidant enzymes.

Kidney sections of the control rodents showed normal architecture of tubules while the Potassium dichromate group showed severe glomerular degeneration, vacuolization, tubular casts and necrosis. However, pre-treatment of rats with extract at 100 mg/kg bwt showed a moderate reduction of features of injury in the kidney histology. Additionally, pre-treatment of rats with extract at 300 and 1000 mg/kg bwt was associated with profound decrease in renal injury similar to control group. Pre-treatment of rats with extract offered a protective effect against renal damage caused by Potassium dichromate.

In conclusion, the ethanolic stem bark extract of *Terminalia ivorensis* protects against Potassium dichromate – induced nephrotoxicity in rats. The nephroprotective effect of *Terminalia ivorensis* could be partly due to obliteration of oxidative stress by increasing levels of antioxidant enzymes.

Declaration of Competing Interests

The authors have no competing interest

Acknowledgments

Authors are grateful to Mr. Thomas Ansah and Mr. Clifford Asare, KNUST Faculty of Pharmacy and Pharmaceutical Sciences, College of Health Science, Kwame Nkrumah University of Science and Technology, and Tracey Willox and Savannah Jacobs of School of Pharmacy and Life Sciences, Robert Gordon University, Aberdeen, UK for their technical support.

Funding

Authors had no funding

References

- [1] A. Whelton, Nephrotoxicity of nonsteroidal anti-inflammatory drugs: physiologic foundations and clinical implications, *Am. J. Med.* 106 (1999) 13S–24S.
- [2] M.-P. Mingeot-Leclercq, P.M. Tulkens, Aminoglycosides: nephrotoxicity, *Antimicrob. Agents Chemother.* 43 (1999) 1003–1012.
- [3] G. Deray, Amphotericin B nephrotoxicity, *J. Antimicrob. Chemother.* 49 (2002) 37–41.
- [4] V. Jha, G. Garcia-Garcia, K. Iseki, Z. Li, S. Naicker, B. Plattner, R. Saran, A.Y. Wang, C.W. Yang, Chronic kidney disease: global dimension and perspectives, *Lancet.* 382 (2013) 260–272.
- [5] A.D. Aikins, Ghana's neglected chronic disease epidemic: a developmental challenge, *Ghana Med. J.* 41 (2007) 154–159.
- [6] H.M. Burkill, *The Useful Plants of West Tropical Africa*, 1, Families AD. Royal Botanic Gardens, 1985.
- [7] S. Ouattara, K.E. Kporou, K.A.M. Kra, G.N. Zirihi, J.D. N'guessan, A. Coulibaly, A.J. Djaman, Antifungal activities of *Terminalia ivorensis* A. Chev. bark extracts against *Candida albicans* and *Aspergillus fumigatus*, *J. Intercult. Ethnopharmacol.* 2 (2013) 49–52.
- [8] J.E. Safra, Wound, *The New Encyclopaedia Britannica*, 5th ed, Encyclopaedia Britannica Inc, USA, 2003, pp. 762–763.
- [9] K.O. Akinyemi, O.K. Oluwa, E.O. Omomigbehin, Antimicrobial activity of crude extracts of three medicinal plants used in South-West Nigerian folk medicine on some food borne bacterial pathogens, *Afr. J. Trad. CAM* 3 (2006) 13–22.
- [10] I. Etukudo, *Ethnobotany: Conventional and Traditional Uses of Plants*, The Verdicts Press, Uyo, 2003, p. 41.
- [11] M.M. Iwu, B.N. Anyanwu, Phytotherapeutic profile of Nigerian herbs, anti-inflammatory and anti-arthritic agents, *J. Ethnopharmacol.* 6 (1982) 263–274.
- [12] C. Ansah, A. Moomin, K.B. Mensah, *Terminalia ivorensis* A. Chev. ethanolic stem bark extract protects against gentamicin-induced renal and hepatic damage in rats, *J. App. Pharm. Sci.* 6 (4) (2016) 175–182.
- [13] W. Mertz, Chromium in human nutrition: a review, *J. Nutr.* 123 (1993) 626–633.
- [14] X.F. Wang, M.L. Xing, Zhu X ShenY, H Xu L, Oral administration of Cr (VI) induced oxidative stress, DNA damage and apoptotic cell death in mice, *Toxicology* 228 (2006) 16–23.
- [15] K.C.D. Casarett, Doull's Toxicology, *The Basic Science of Poisons*, 476, 7th edition, McGraw – Hill Medical Publishing Division, New York, USA, 2008, pp. 11–34.

- [16] A. Sofowora, Medicinal Plants and Traditional Medicinal In Africa, 2nd Ed, Sunshine House, Ibadan, Nigeria: Spectrum Books Ltd, 1993, pp. 134–156. Screening Plants for Bioactive Agents.
- [17] . Guidelines for the testing of chemicals/ section 4: health effects test no. 423: acute oral toxicity - acute toxic class method, in: Organization for Economic Cooperation and Development, Paris, France, 2002.
- [18] M. Aslam, R. Dayal, R. Javed, S.A. Parray, M Jetley S andSamim, Nephroprotective effects of peucedanum grande against acute renal failure induced by potassium dichromate in rats, Int. J. Pharm. Sci. Drug Res. 5 (2013) 45–49.
- [19] G.L. Ellman, Tissue sulfhydryl groups, Arch. Biochem. Biophys. 82 (1959) 70–77.
- [20] Y. Sun, L. Oberley, Y Li, A simple method for clinical assay of superoxide dismutase, Clin. Chem. 34 (1988) 497–500.
- [21] A.K. Sinha, Colorimetric assay of catalase, Anal. Biochem. 47 (1972) 389–394.
- [22] H. Ohkawa, N. Ohishi, K. Yagi, Assay for lipid peroxides in animal tissues by thiobarbituric acid reaction, Anal. Biochem. 95 (1979) 351–358.
- [23] M. Senoglu, E.B. Kurutas, I. Altun, Y. Atli, V Nacitarhan, Myeloperoxidase activities in polymorphonuclear leukocytes in lumbar disc disease, J. Neurol. Sci. [Turk.] 26 (2009) 292–297.
- [24] K. Annan, K. Sarpong, C. Asare, R. Dickson, K.I. Amponsah, B. Gyan, M. Ofori, S.Y Gbedema, In vitro anti-plasmodial activity of three herbal remedies for malaria in Ghana: *adenia cissampeloides* (Planch.) Harms., *Terminalia ivorensis* A. Chev, and *Elaeis guineensis* Jacq., Pharmacog. Res. 4 (2012) 225–229.
- [25] J.M. Agbedahunsi, I. Anao, C.O. Adewunmi, S.L Croft, Trypanocidal properties of *Terminalia ivorensis*. A. Chev. (Combretaceae), Afr. J. Trad. CAM 3 (2006) 51–56.
- [26] I.I. Johnny, N.J. Ekong, J.E Okon, Phytochemical screening and anti-hyperglycaemic activity of ethanolic extract of *Terminalia ivorensis* A. Chev. Leaves on Albino Wistar Rats, Global Adv. Res. J. Med. Med.Sci. 3 (2014) 186–189.
- [27] E.G.C. Clarke, M. L. Clarke, Garner, Veterinary Toxicology, Ed., 1, Baillière Tindall, London, 1975, p. 438.
- [28] O. Sitapha, KRAAK. Mathieu, K.K. Elisée, Z.G. Noël, Y.H. Félix, N.J. David, D.A. Joseph, Comparative study of chromatographic fractions activities from *Terminalia ivorensis* and ketoconazole as standard antifungal on in vitro growth of Trichophyton Mentagrophytes Var. Interdigitale, J. Drug Del. Ther. 3 (2013) 18–21.
- [29] I. Abreu, D.E. Caballi, Superoxide dismutases – a review of the metal-associated mechanistic variations, Biochim. Biophys. Acta 1804 (2010) 263–274.
- [30] W.O. Larry, R.B. Garry, Role of superoxide dismutase in cancer: a review, Cancer Res. 39 (1979) 1141–1149.
- [31] V. Sivanandham, Free radicals in health and diseases – a mini review, Pharmacologyonline 1 (2011) 1062–1077.
- [32] C.J. Weydert, J.J. Cullen, Measurement of superoxide dismutase, catalase and glutathione peroxidase in cultured cells and tissue, Nat. Protoc. 5 (2009) 51–66.
- [33] P.A.E. Main, M.T. Angley, C.E. O'Doherty, P. Thomas, M Fenech, The potential role of the antioxidant and detoxification properties ofglutathione in autism spectrum disorders: a systematic review and meta-analysis, Nutr. Metab. 9 (2012) 1–37.
- [34] D.M. Townsend, K.D. Tew, H Tapiero, The importance of glutathione in human disease, Biomed. Pharmacother. 57 (2003) 145–155.
- [35] A.W. Girotti, Lipid hydroperoxide generation, turnover, and effector action in biological systems, J. Lipid Res. 39 (1998) 1529–1542.
- [36] A.S. Adejuwon, O. Femi-Akinlosotu, J.O. Omirinde, O.R. Owolabi, A.M Afodum, Launaea taraxacifolia Ameliorates Cisplatin – induced Hepato – renal injury, Eur. J. Med. Plants 4 (2014) 528–541.
- [37] J. Arnhold, Free radicals – friends or foes? Properties, functions and secretions of human myeloperoxidase, Biochemistry 69 (2004) 8–15.
- [38] K.D. Metzler, T.A. Fuchs, W.M. Nauseef, D. Reumaux, J. Roesler, I. Schulze, V. Wahn, V. Papayannopoulos, A Zychlinsky, Myeloperoxidase is required for neutrophil extracellular trap formation: implications for innate immunity, Blood 117 (2011) 953–959.
- [39] L.R. Amy, T. Everett, P.Y. Joannes, E.G. Andrew, A.J. Jason, Z. Hao, A.P.J. Kirkwood, G.V Haris, The role of neutrophil myeloperoxidase in models of lung tumor development, Cancers 6 (2014) 1111–1127.